



## Successful implantation techniques of S-ICD



**Ji Hyun Lee, MD, PhD, CEPS**

Seoul National University Bundang Hospital

# Korean Heart Rhythm Society

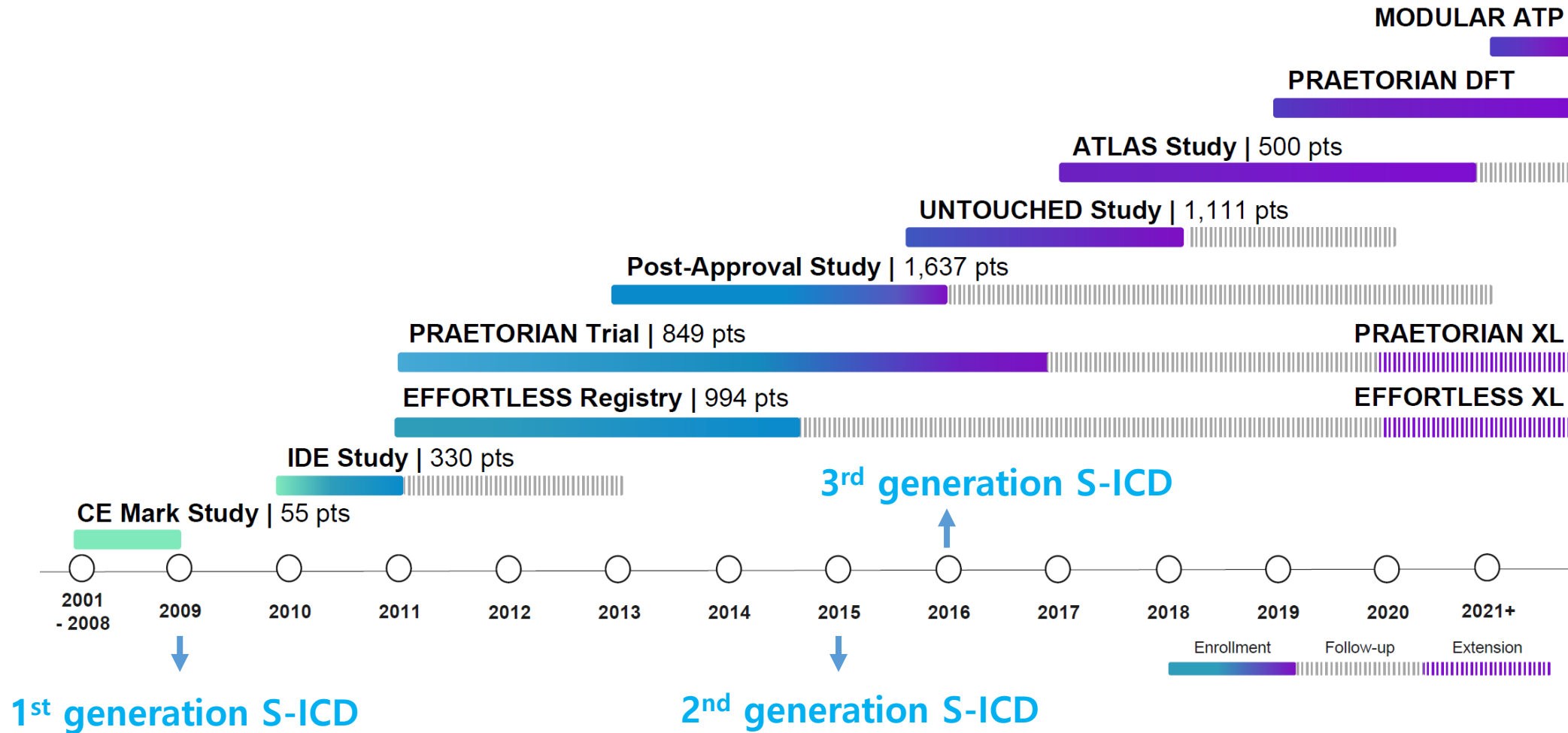
## COI Disclosure

*Ji Hyun Lee*

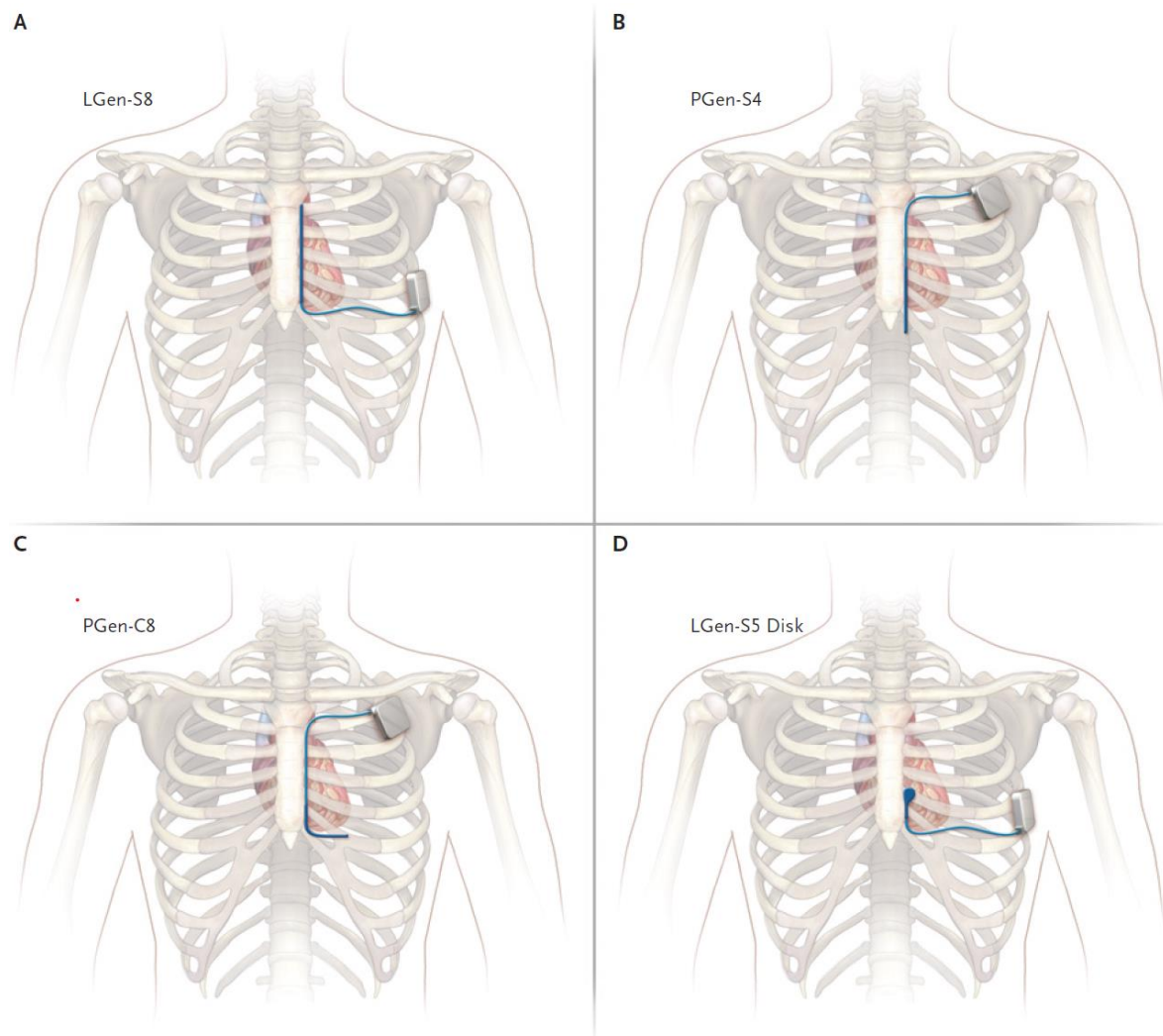
The authors have no financial conflicts of interest  
to disclose concerning the presentation



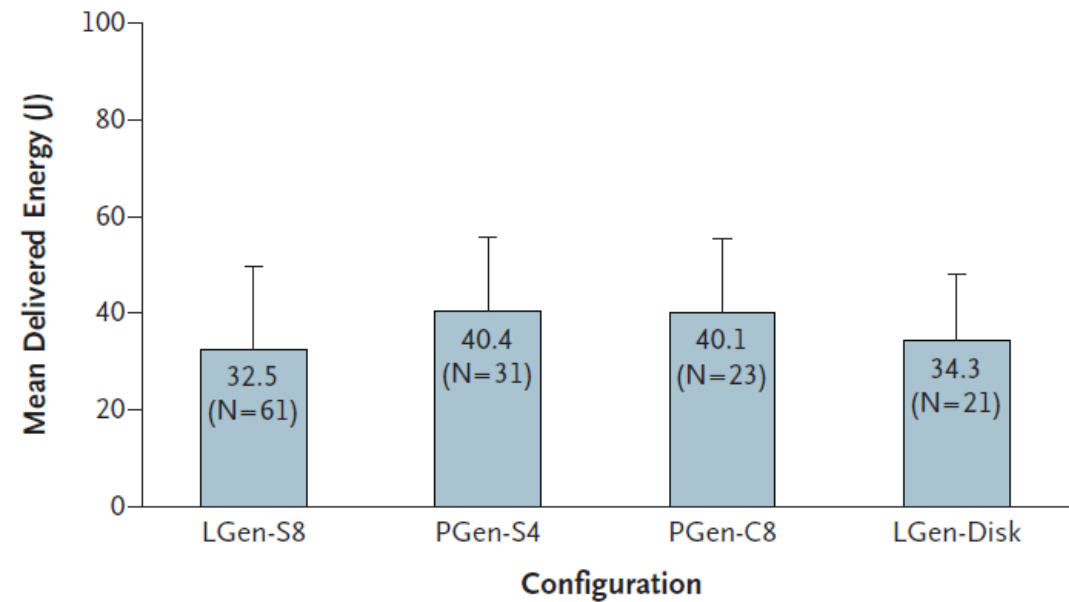
# History of subcutaneous ICD



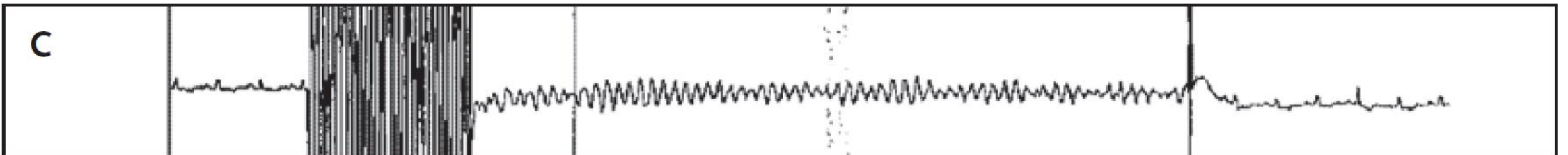
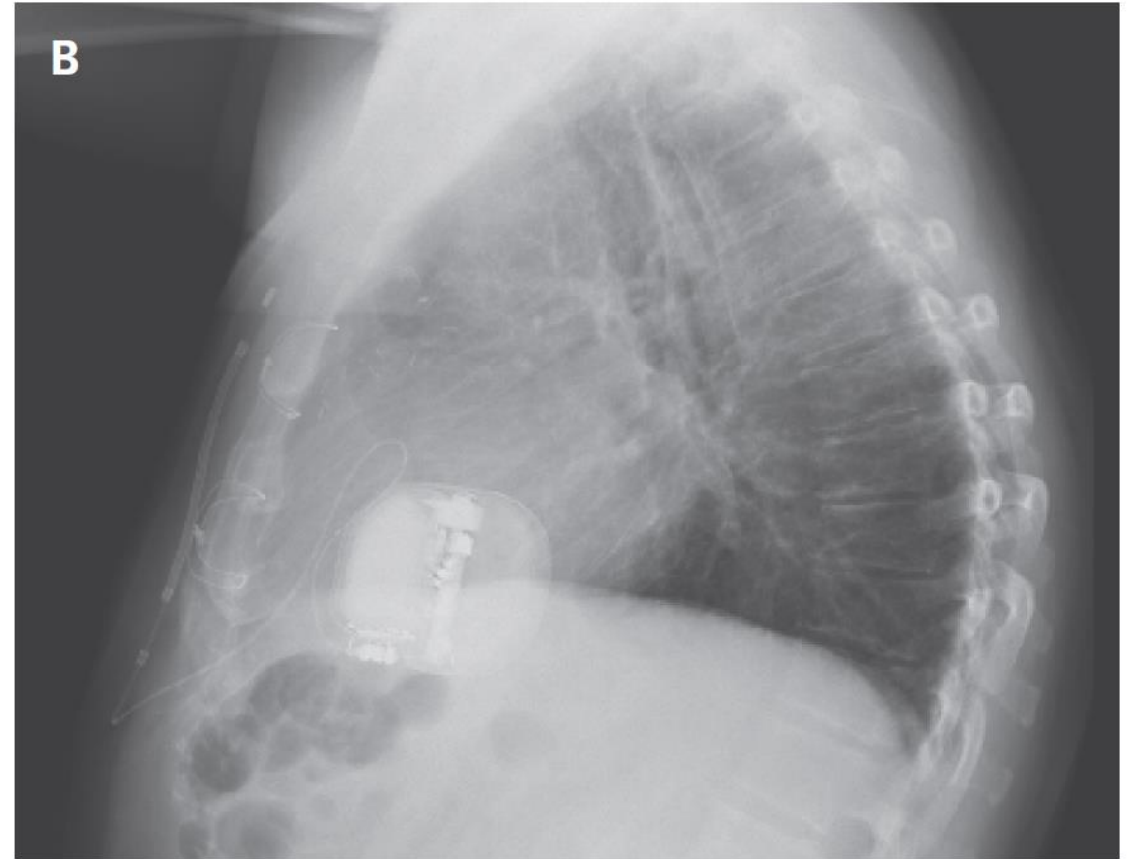
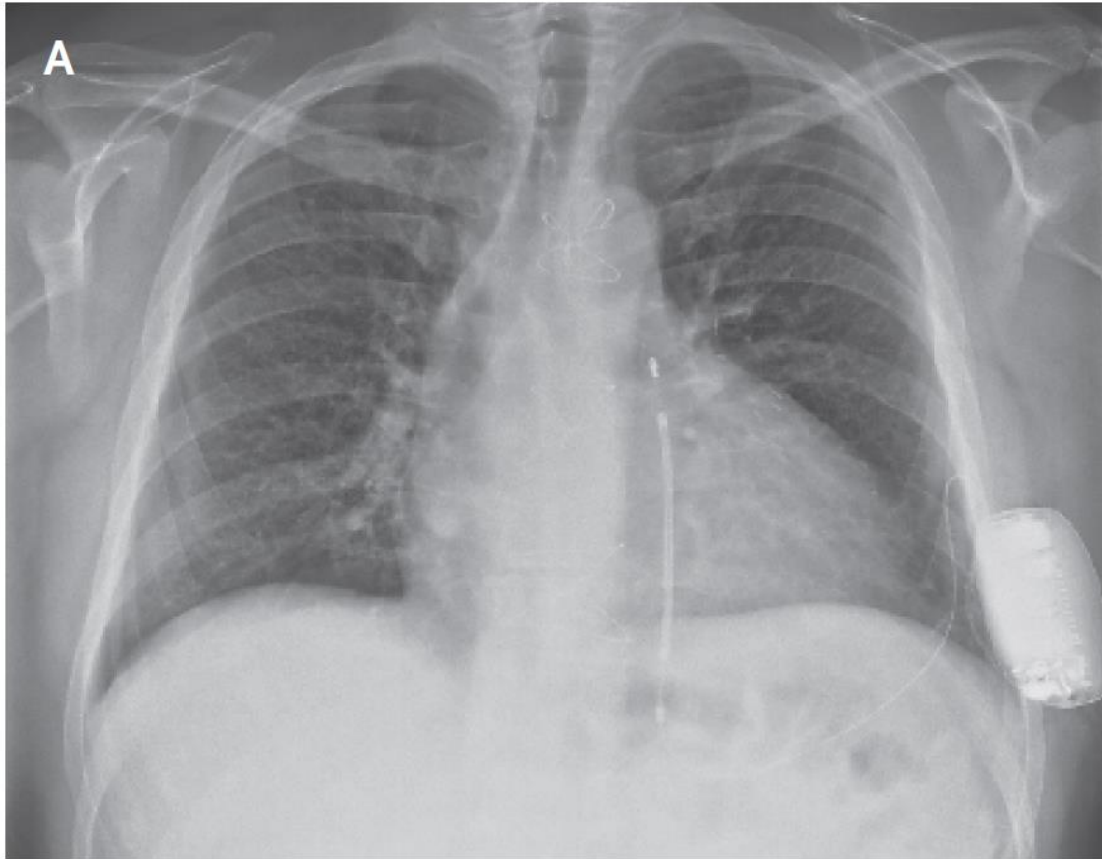
# Four configurations of a subcutaneous ICD



A Delivered Energy



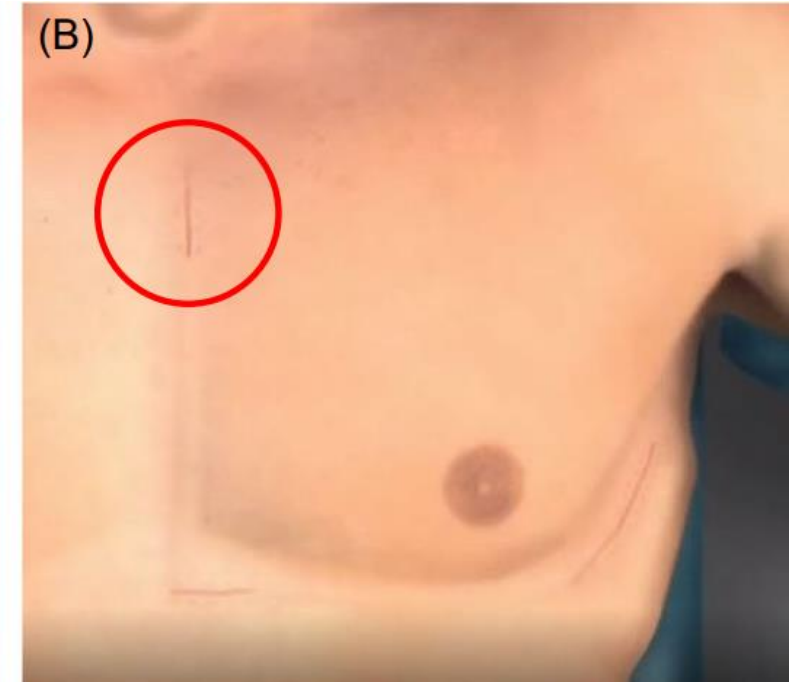
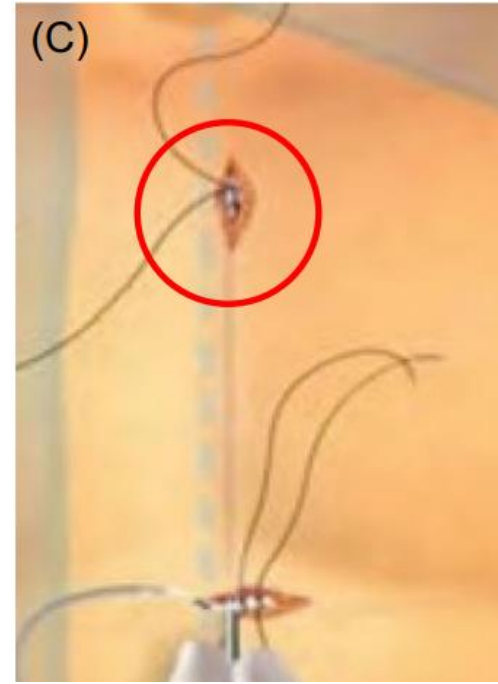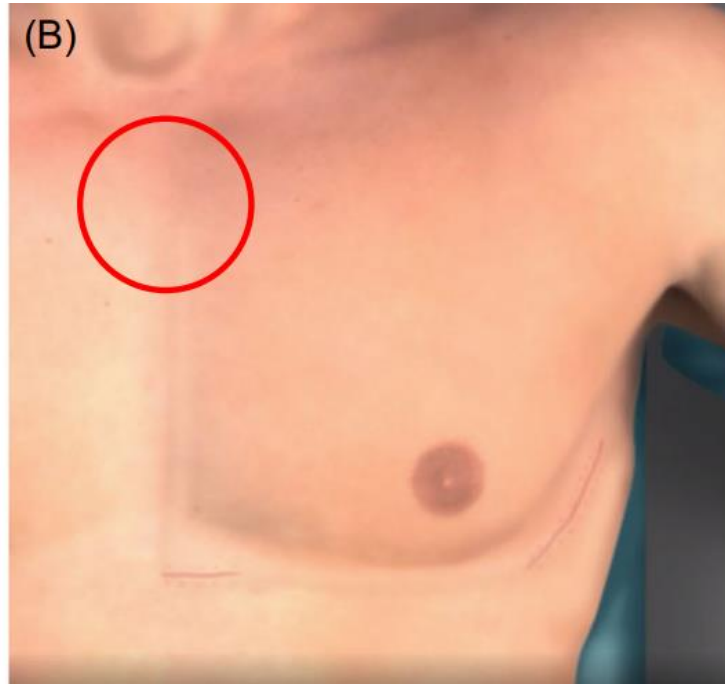
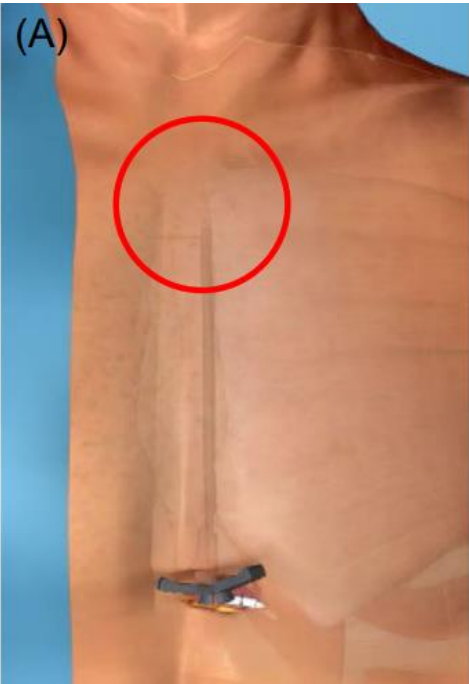
# Chest radiographs after S-ICD



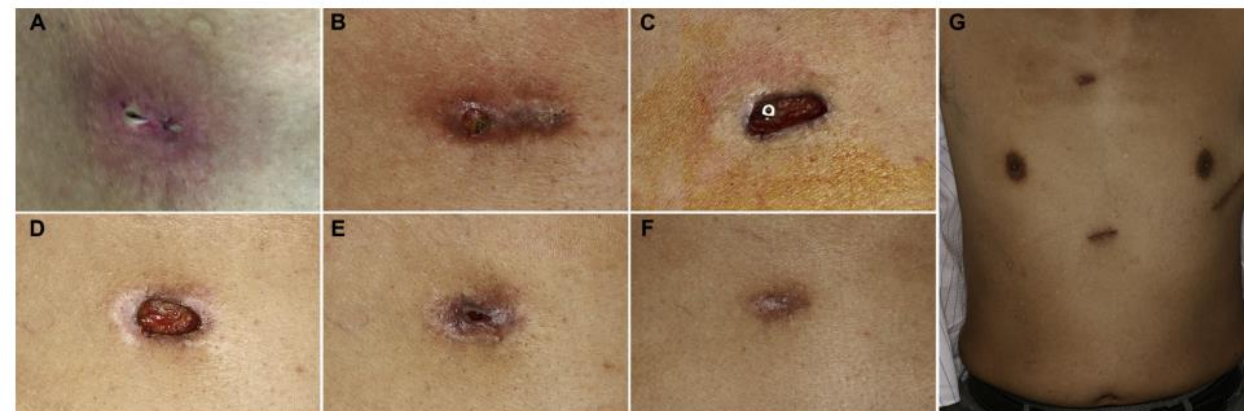
# 2 incision vs 3 incision

## 2 incision technique

## 3 incision technique



# S-ICD infection site



**Table 3** Characteristics of Patients With S-ICD Infections

Patient	A	B	C	D	E	F	G
Age, yrs	51	59	53	36	23	43	14
Diagnosis	Ischemic CMP	IVF	Ischemic CMP	TGA	Genetic arrhythmia syndrome	Ischemic CMP	Dilated CMP
ICD indication	Primary prevention	Secondary prevention	Primary prevention	Primary prevention	Primary prevention	Primary prevention	Secondary prevention
Predisposing factors	—	Poor cicatrization e.c.i.	—	Small hematoma	Manipulation suture in wound	DM and obesity (large breast over pocket wound)	Ongoing leg infection after treatment compartment syndrome and ECMO
Manifestation	Redness, pus, and pain	Redness, pus, and large wound (tip visible)	Redness, pain, and fever	Redness and pain	Redness, pain, and fever	Redness, pus, and little wound	Redness and pus
Start site	Xiphoid	Sternomanubrium	Sternomanubrium	Sternomanubrium	Sternomanubrium	Pocket	Pocket
No. of days post implant	28	34	37	24	28	12	126
Systemic or local infection	Local	Local	Systemic	Local	Systemic	Local	Local
Lead and/or generator	Lead and generator	Lead	Lead	Lead	Lead and generator	Lead and generator	Generator
Infective organism	<i>S. Aureus</i>	<i>S. Aureus</i>	<i>S. Aureus</i>	<i>S. Aureus</i>	<i>S. Aureus</i>	Unknown	<i>S. Aureus</i>
Antibiotics	Flucloxacillin iv.	Flucloxacillin iv.	Flucloxacillin iv.	Flucloxacillin iv.	Flucloxacillin iv.	Flucloxacillin iv.	Flucloxacillin iv.
Reimplantation	TV-ICD	TV-ICD	TV-ICD	S-ICD	S-ICD	S-ICD	TV-ICD

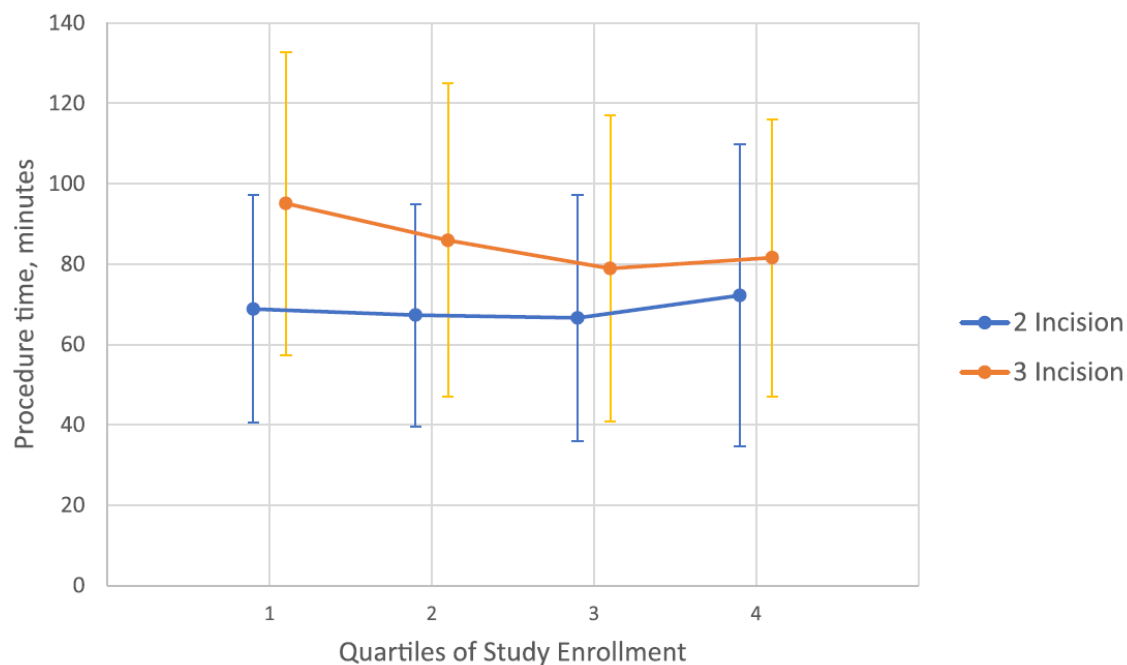


# 2 incision vs 3 incision in the S-ICD post approval study

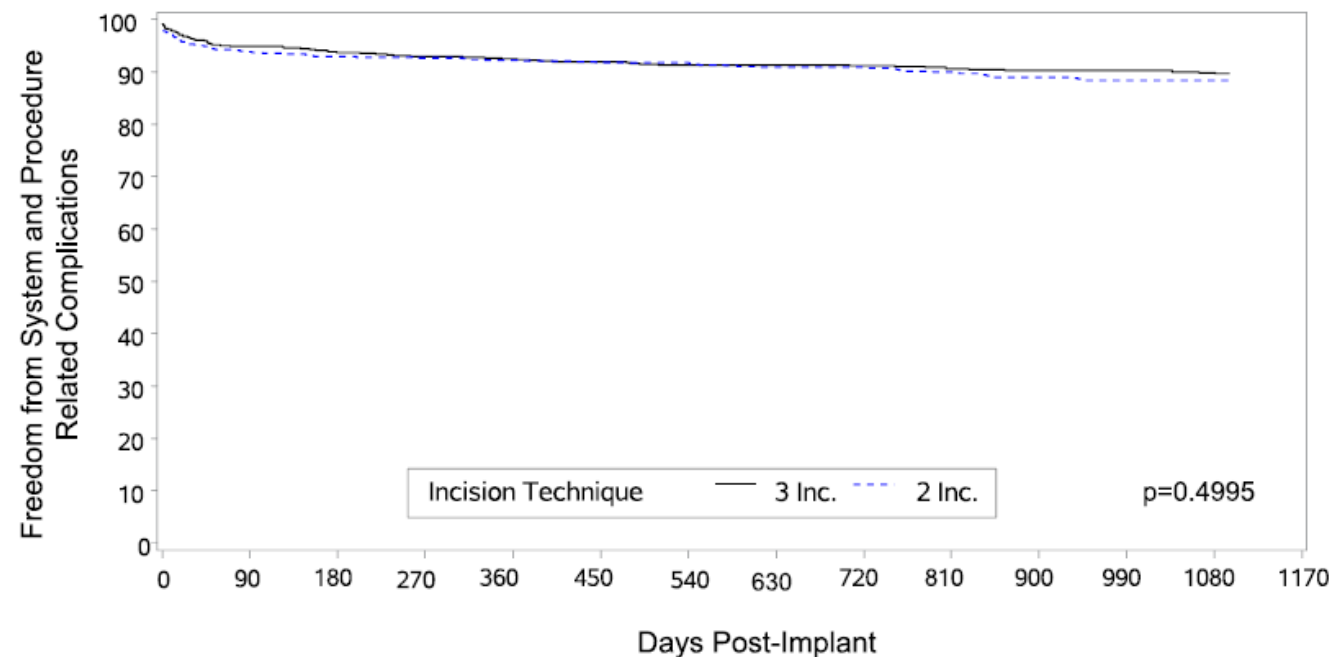
2 incision technique: 854

3 incision technique: 782

Procedure Time by Quartiles

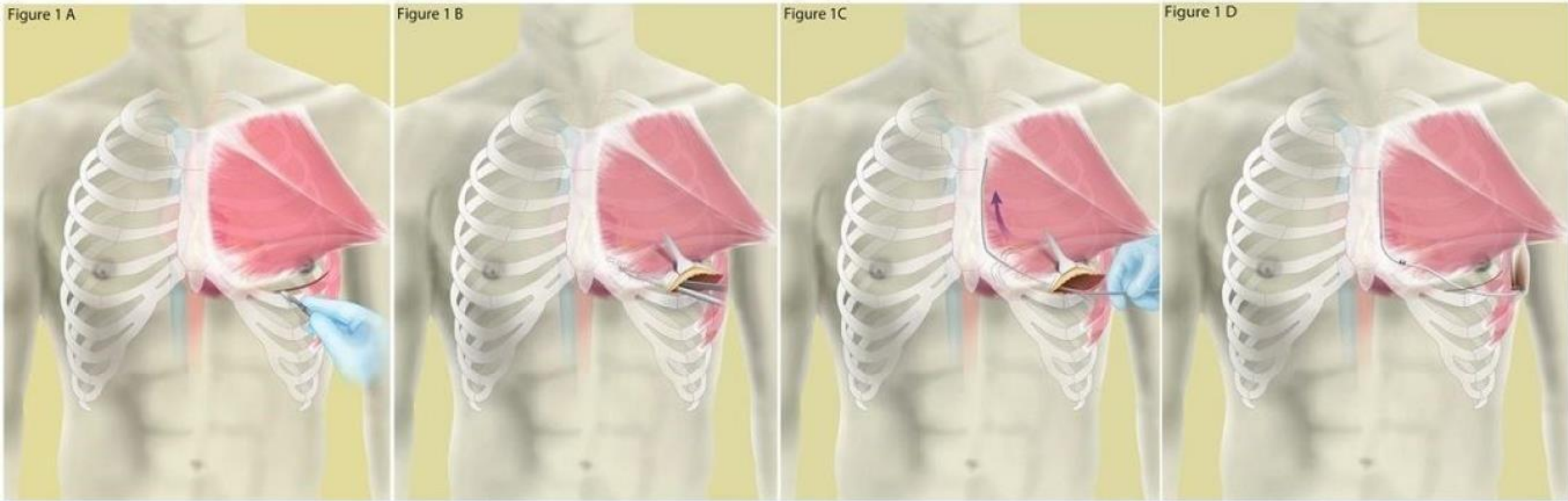


Kaplan-Meier Analysis of Freedom from System and Procedure-Related Complications

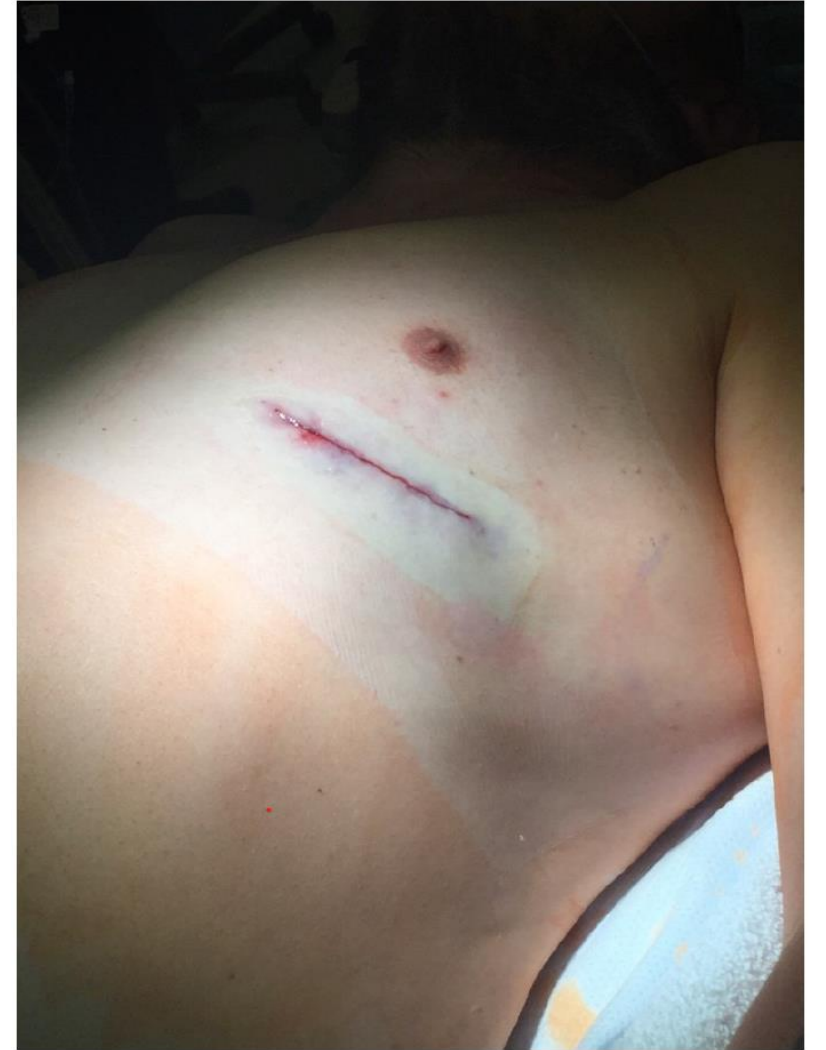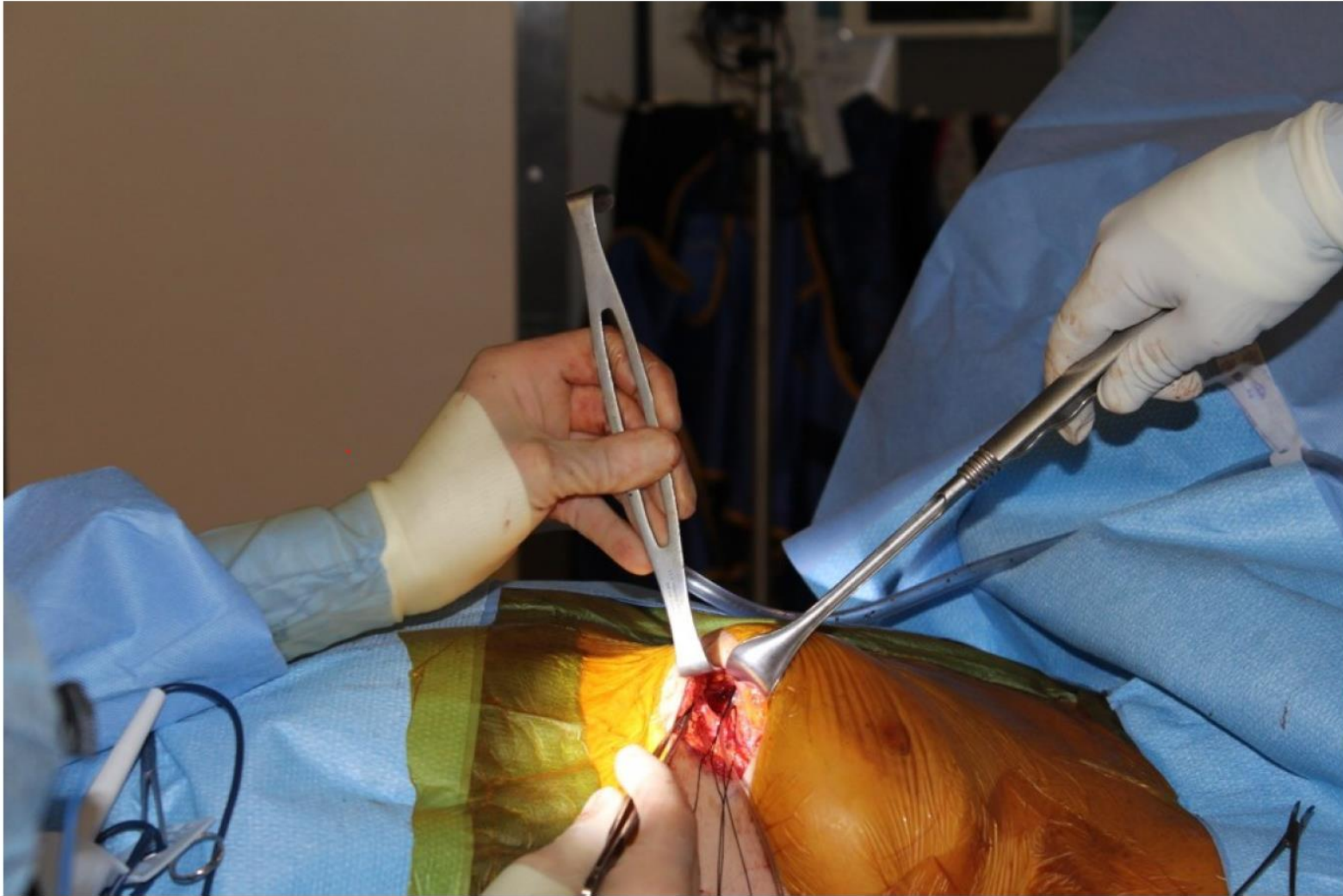




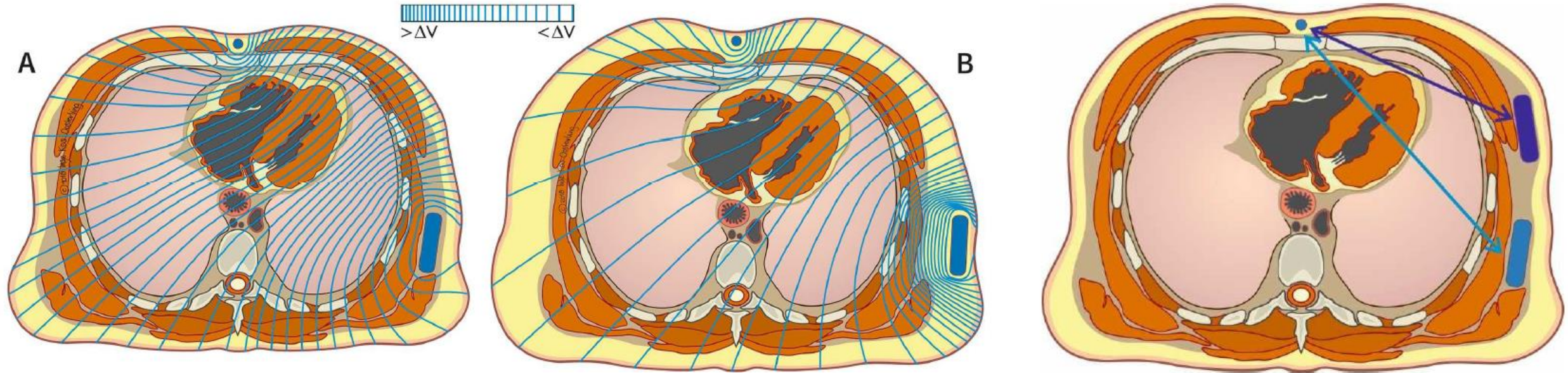
# Single incision technique



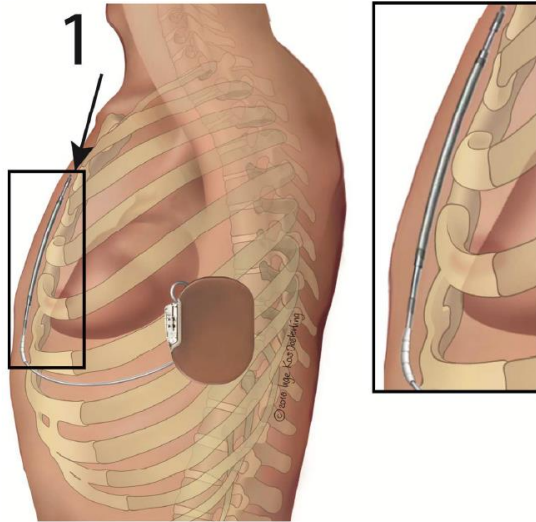
# Single incision technique



# Impact of fat tissue and generator location on electrical shock

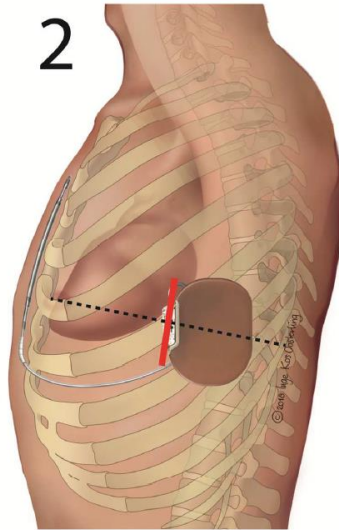


# PRAETORIAN score



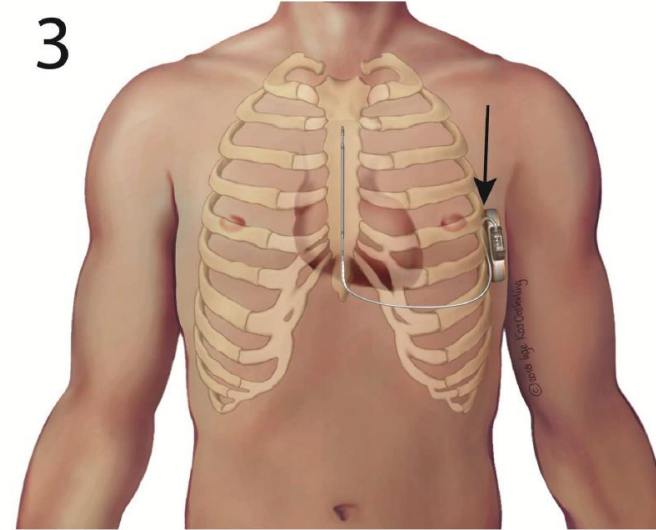
**Step 1)**  
 Determine the number of coil widths of fat tissue between the **nearest** half of the S-ICD coil and the sternum or ribs.

≤ 1	coil-width	<b>30</b>
> 1 ≤ 2	coil-widths	<b>60</b>
> 2 ≤ 3	coil-widths	<b>90</b>
> 3	coil-widths	<b>150</b>



**Step 2)**  
 Determine the position of the S-ICD generator in relation to the mid-line (**red line**).

Generator is on or posterior of the mid-line	<b>x 1</b>
Entire generator is anterior of the mid-line	<b>x 2</b>
Entire generator is > 1/2 length anterior	<b>x 4</b>

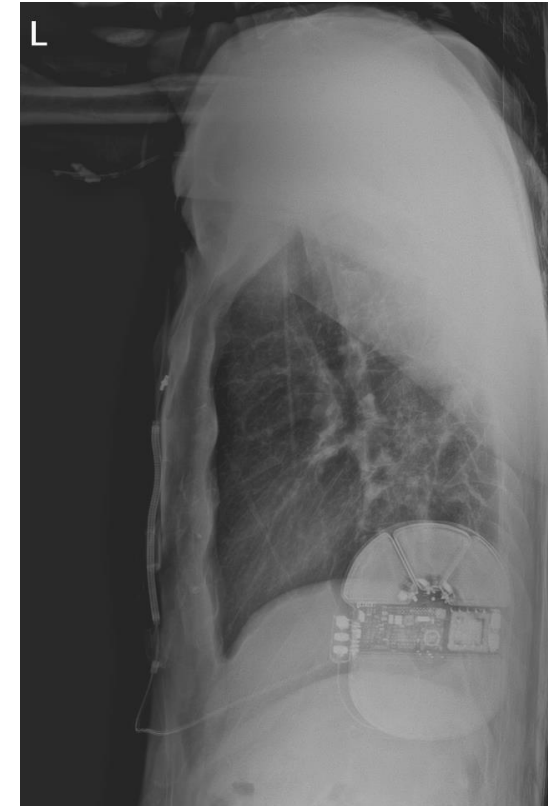


**Step 3)**  
 Determine the amount of fat tissue between the **nearest** point of the generator and the thoracic wall.

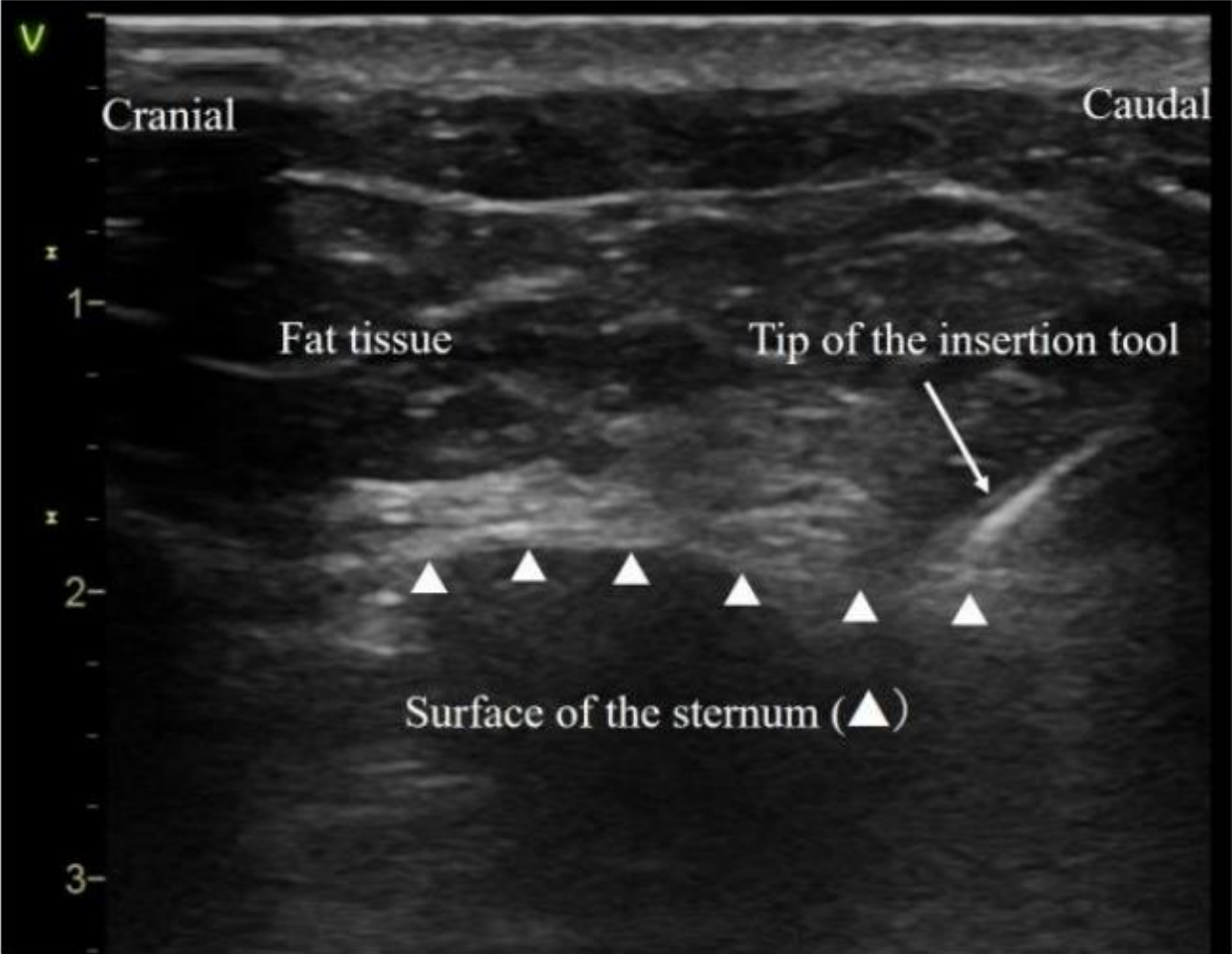
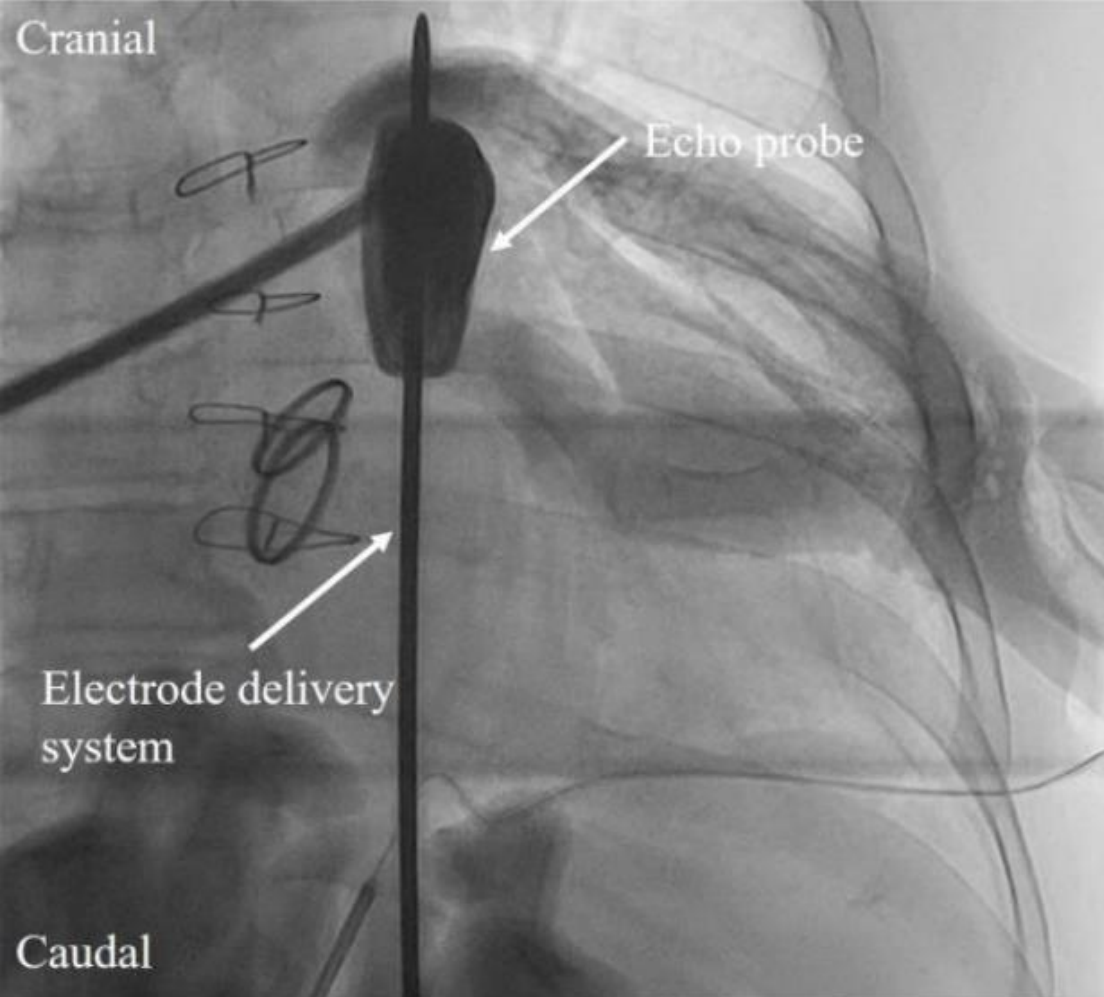
< 1 generator-width	<b>x 1</b>
≥ 1 generator-width	<b>x 1.5</b>

**Step 4)**  
 PRAETORIAN score ≥ 90:  
 BMI ≤ 25 kg/m<sup>2</sup>      - 40  
 BMI ≥ 25 kg/m<sup>2</sup>      = **Final score**

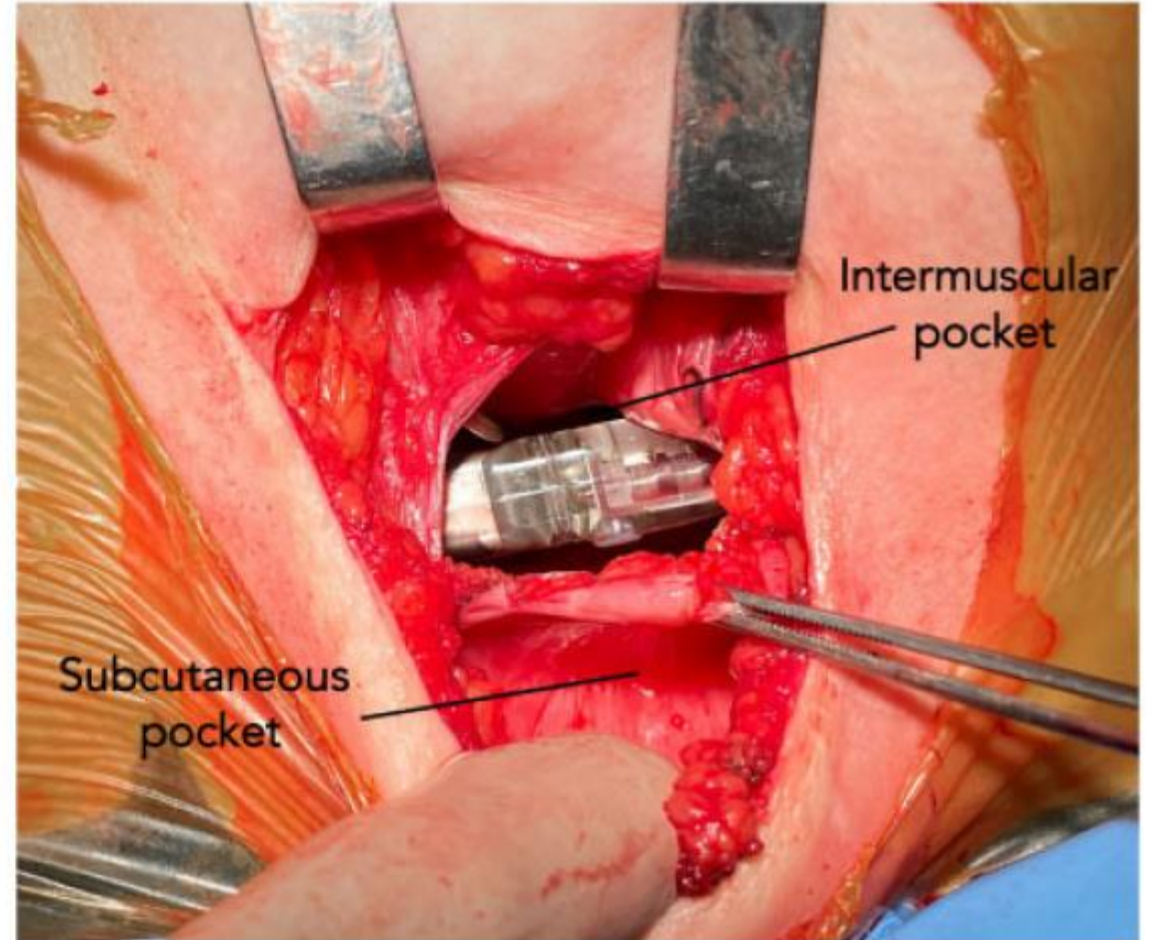
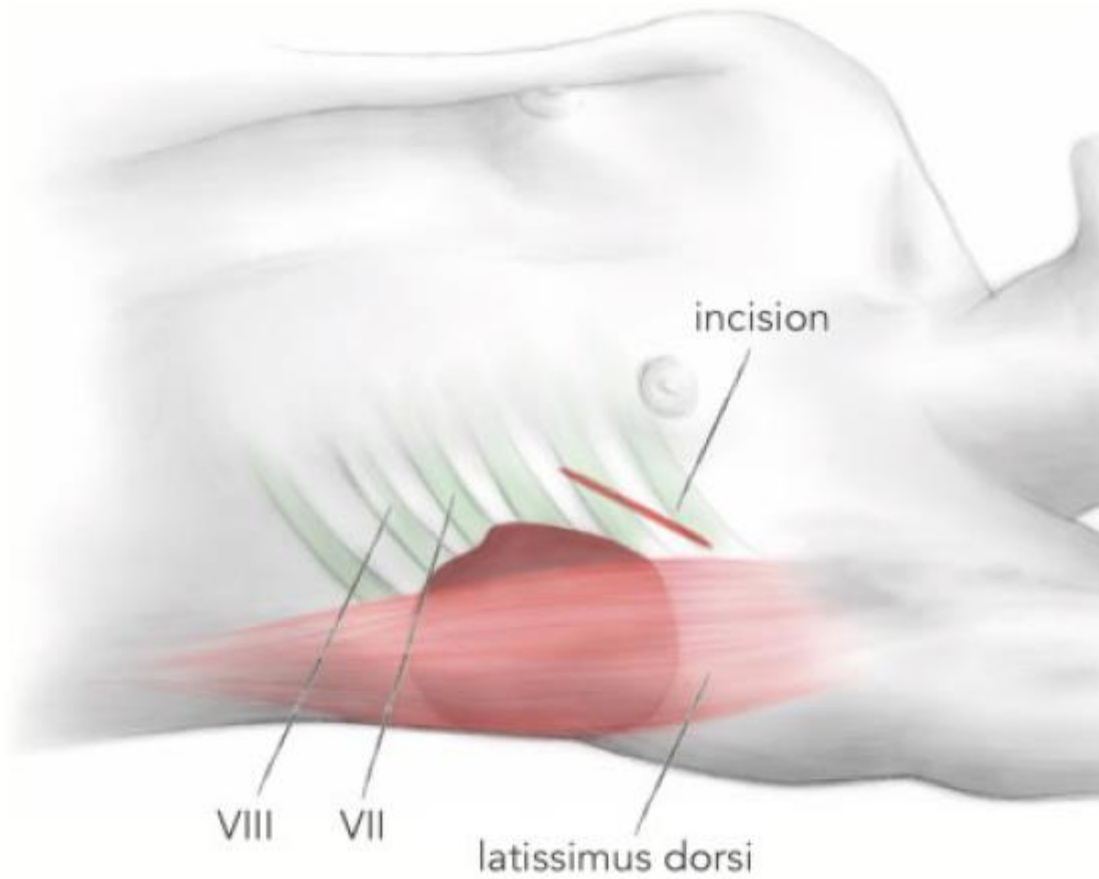
<b>Final PRAETORIAN score</b>	
<b>&lt; 90</b>	<b>Low risk of conversion failure</b>
<b>90 &lt; 150</b>	<b>Intermediate risk of conversion failure</b>
<b>≥ 150</b>	<b>High risk of conversion failure</b>



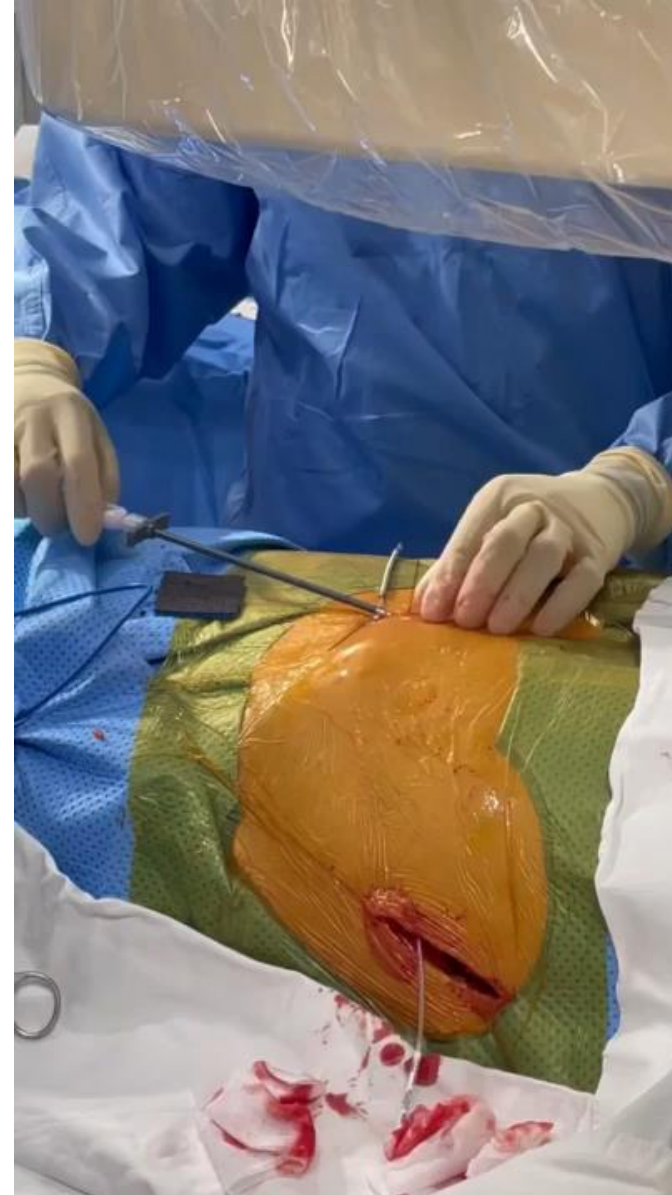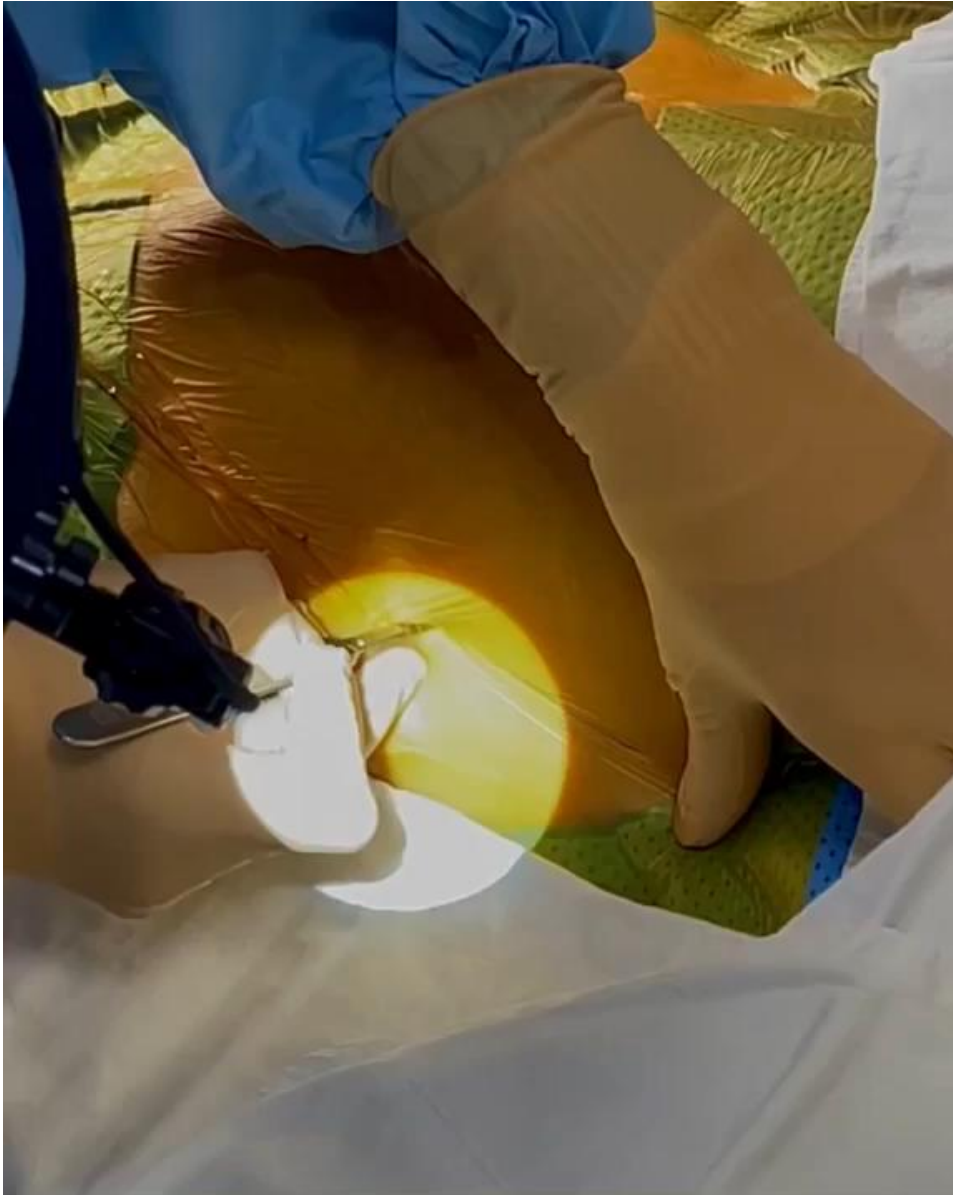
# Echo-Guided Parasternal Tunneling



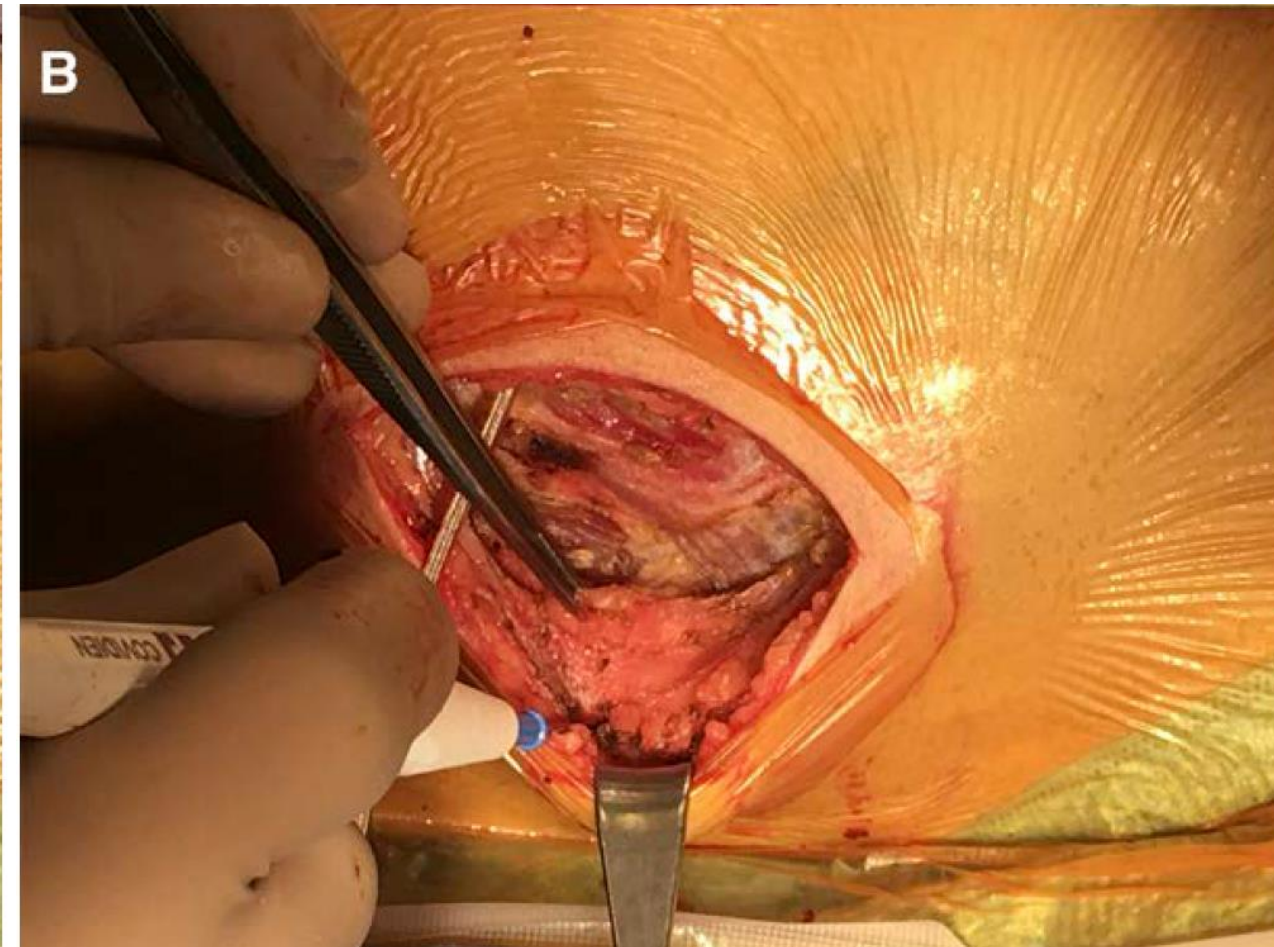
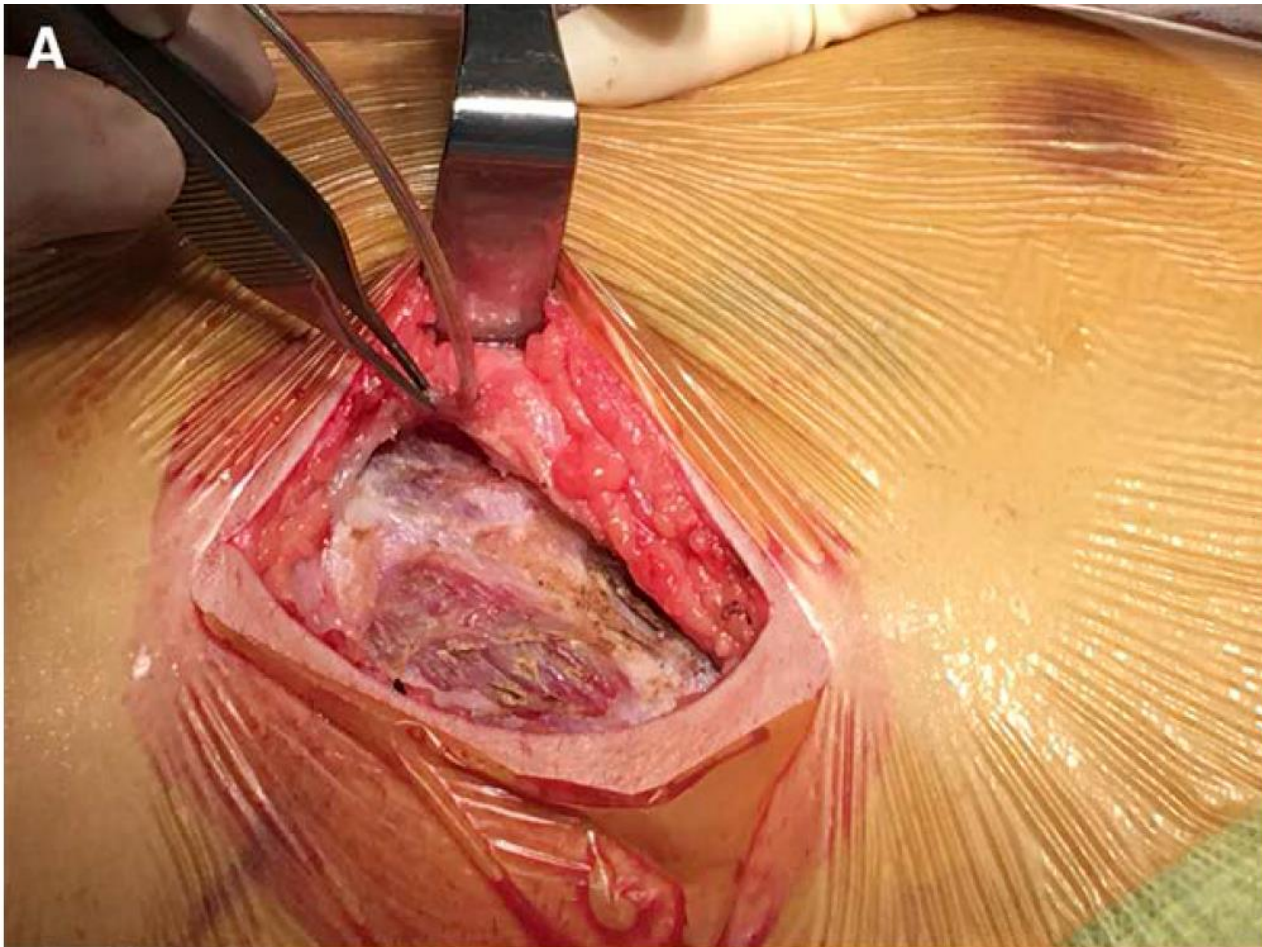
# ICD in intermuscular pocket



# Pocket formation and parasternal tunneling

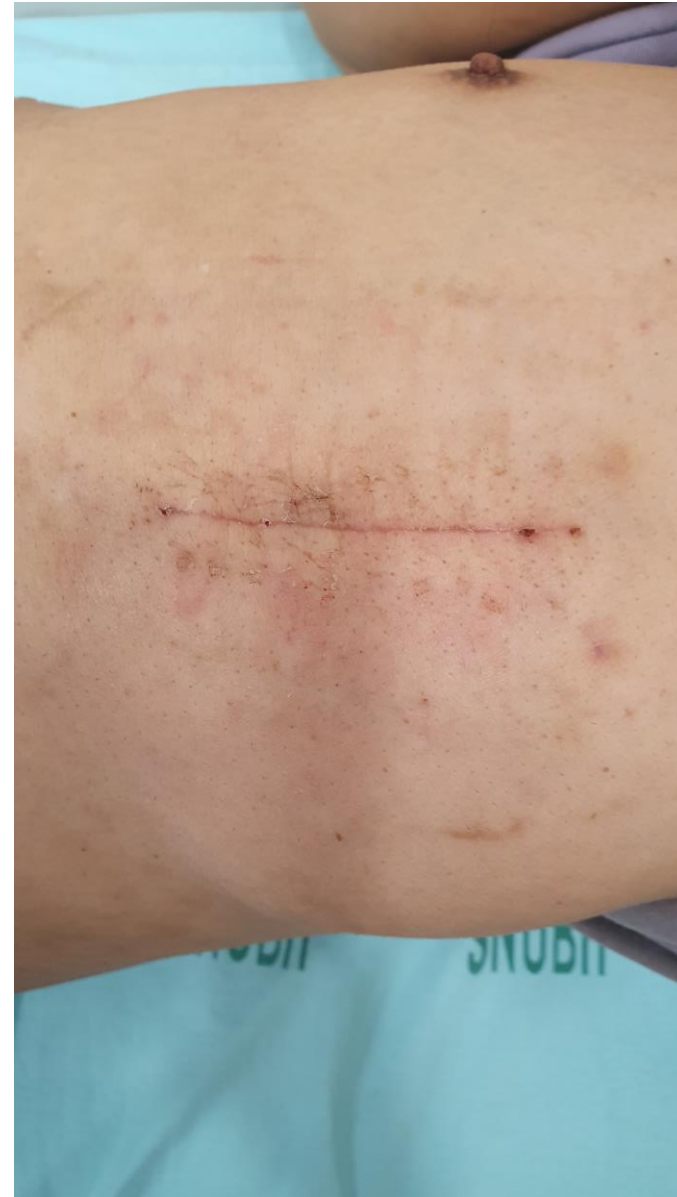
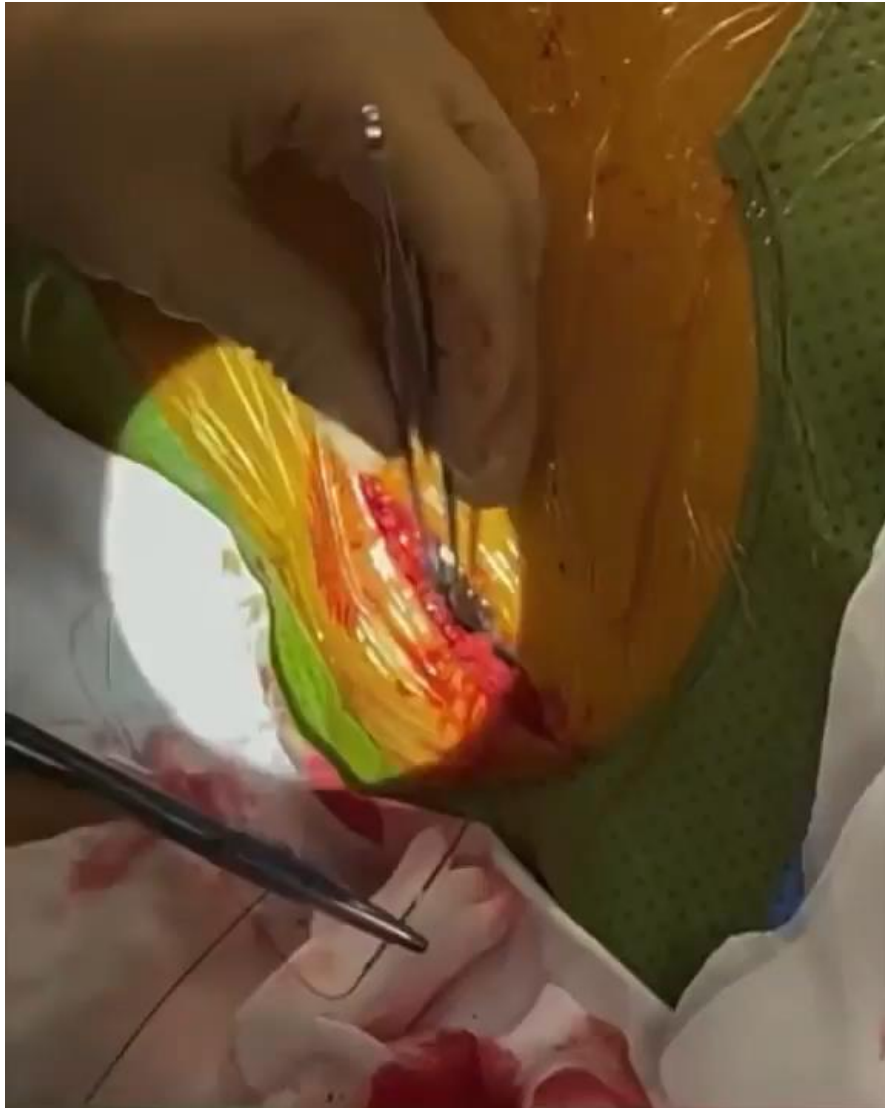
# Fascial layer from serratus anterior muscle





# Wound closing



# Summary

1. Implant the generator in intermuscular space
2. Place the ICD lead and the generator to the chest wall as close as you can
3. Close the fascia tightly
4. Wound closure device may be used to shorten the procedure time.



# Acknowledgement

## Electrophysiologists

- Il-young Oh, MD, PhD
- Youngjin Cho, MD, PhD
- Ji Hyun Lee, MD, PhD

## EP fellow (rotation)

- Ji-suck Park, MD
- Hyung-bum Ahn, MD
- Do-Hyun Kim, MD
- Woong-su Yoon, MD
- Soo-Young Lee, MD
- Jina Choi, MD

## EP assistant

- Sung-wook Kim, RT, CEPS
- Su-ji Kim, RT, CEPS
- Jin-hyung Kim, RN
- Chan-yang Kim, MT
- Hu-lim Kim, MT
- Ga-hyuk Park, RT
- Eun-sung Yoon, MT
- Su-min Lee, RT
- Hyo-mi Chang, MT
- Yu-ri Choi, MT
- Ji-yun Whang, MT, CEPS/CCDS

## CIED lab

- Ji-Hye Yoo, RN
- Jung-Hwa Lee, RN
- Jin Ju Yang, MT

## EP PA

- Myung-sun Moon, RN
- Ok Choi, RN, CEPS

## EP research

- Eun-jung An, HIM
- Yun-ju Kim, RN
- Eun-ji Yoon, HIM
- Minji Yeo, RN